

Minimally invasive aortic valve replacement using the Perceval S sutureless valve

Martin Misfeld

Department of Cardiac Surgery, Heart Center, University of Leipzig, Leipzig, Germany

Correspondence to: Martin Misfeld, MD, PhD. Professor and Co-Director, Department of Cardiac Surgery, Heart Center, University of Leipzig, Struempellstrasse 39, 04289 Leipzig, Germany. Email: martinmisfeld@yahoo.com.



Submitted Feb 02, 2015. Accepted for publication Feb 03, 2015.

doi: 10.3978/j.issn.2225-319X.2015.02.07

View this article at: <http://dx.doi.org/10.3978/j.issn.2225-319X.2015.02.07>

The term “sutureless aortic valve” (su-AV) describes a type of valve which facilitates anchoring of bioprostheses in the aortic position without use of conventional sutures. Although all valve prostheses used for transcatheter aortic valve implantation or replacement (TAVI or TAVR) follow the same principle, they are implanted by wire-based techniques as opposed to su-AVs, which are implanted by conventional surgical techniques. Because all commercially available su-AVs are not all truly sutureless, another general term “rapid deployment valve” has also been used.

There are three commercial available su-AV substitutes (Figure 1), the 3F Enable (Medtronic, Minneapolis, USA), the Perceval S (Sorin, Saluggia, Italy), and the Intuity valve (Edward Lifesciences, Irvine, USA). These valves are implanted after excision of the native aortic valves and decalcification of the aortic annulus. So far, these valves are used only in patients with aortic stenosis or combined aortic valve disease. Isolated aortic regurgitation is currently not an indication for su-AVs.

Clinical vignette

A 78-year-old female patient was admitted to our hospital with a history of syncope and dyspnea on exertion (NYHA Class III). Investigations revealed combined aortic valve disease with severe aortic stenosis and mild aortic regurgitation (Video 1). Pre-operative echocardiography revealed good left ventricular (LV) function with LV hypertrophy, a max/mean pressure gradient of 73/44 mmHg across the aortic valve and an aortic valve area (AVA) of 0.8 cm² of a tricuspid aortic valve.

Surgical technique

Following induction of anesthesia, an L-shaped partial upper sternotomy into the 4th right intercostal space was performed using a conventional saw. The distal proximal aortic arch was cannulated in standard fashion. Venous cannulation was performed using a two-stage venous cannula.

The correct location of the aortic incision is one of the important steps to be observed during implantation of the Perceval S valve. Because the valve has to be anchored at the sinotubular junction besides the annulus, the aortic incision should be made well above it.

Cold blood cardioplegia was used for myocardial protection. A transverse aortic incision was made and care is taken not to incise the aorta too proximally towards the aortic root, especially in the lateral and posterior aspects. Adequate exposure of the aortic valve is essential. The aortic valve cusps were excised and the annulus decalcified. The next important step is proper sizing of the valve. Care has to be taken to size the diameter of the functional annulus and not of the LV outflow tract. In this case, a 21-mm Perceval S valve was chosen, representing size S.

Guiding sutures were placed in a symmetric fashion at the nadirs of each sinus. Correct placement of the guiding sutures is the third important step in implantation of the Perceval S valve.

The three guiding sutures were passed through three small green loops located at the level of the annulus of the valve. The valve was then advanced into the aortic root and released. Maintaining the correct position during release is the fourth important step. An initial check was performed to confirm correct the position of the valve.

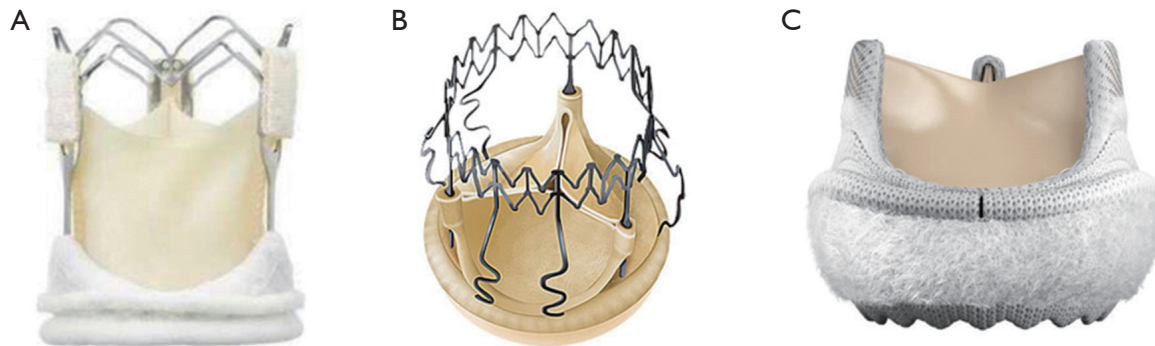


Figure 1 (A) 3F Enable (Medtronic, Minneapolis, USA); (B) Perceval S (Sorin, Saluggia, Italy); (C) Intuity (Edward Lifesciences, Irvine, USA).

Following ballooning of the Perceval S valve, the aorta was closed with a 4x0 monofilament suture. After weaning the patient from cardiopulmonary bypass and decannulation, the sternum was closed with standard wires and the wound was closed in layers.

Intraoperative transesophageal echocardiography revealed an appropriately positioned Perceval S valve without any paravalvular leak. The maximum/mean pressure gradients were 16/8 mmHg with a trace of central regurgitation, which is a typical characteristic of pericardial heart valves.

The patient left the operating room in sinus rhythm without the need for inotropic support and was extubated 3 hours postoperatively. The overall postoperative course was uneventful.

Comments

The concept of sutureless valves is not new, and were first introduced by Magovern and Cromie from the University of Pittsburgh in 1961 (1). They were the first to implant a sutureless mechanical aortic valve substitute in 1962 and demonstrated very good long-term results (2).

The main advantage of su-AVs is the reduced cross-clamp and, therefore, reduced cardio-pulmonary bypass time required for valve implantation, both of which influence perioperative morbidity and mortality especially in complex surgical cases. Furthermore, they are ideal valve substitutes for a minimally invasive approach, because a number of surgical steps, such as placing sutures and tying the knots, are eliminated, thus facilitating AVR through a small incision. Furthermore, the Perceval S valve is an ideal valve substitute for calcified aortic roots, i.e., following previous homograft procedures.

The Perceval S valve requires several crucial steps in

order to achieve optimal outcomes for the patient. Besides aortic incision and sizing, positioning of the guiding sutures and specific aspects during valve release must to be followed. However, implantation of this valve is easy, if these steps are adhered to.

Initial clinical results demonstrated the safety and efficiency of su-AVs, especially through a minimally invasive approach (3-7). Theoretically, these valves may also improve postoperative LV performance, because it may be possible to implant larger valve sizes due to the absence of sutures (8). As some su-AVs have to be crimped or collapsed prior to implantation and dilated by balloon inflation at the time of implantation, the influence of these maneuvers on the long-term performance needs to be determined.

Acknowledgements

Disclosure: The author declares no conflict of interest.

References

1. Magovern GJ, Cromie HW. Sutureless prosthetic heart valves. *J Thorac Cardiovasc Surg* 1963;46:726-36.
2. Magovern GJ, Liebler GA, Park SB, et al. Twenty-five-year review of the Magovern-Cromie sutureless aortic valve. *Ann Thorac Surg* 1989;48:S33-4.
3. Borger MA, Moustafine V, Conradi L, et al. A randomized multicenter trial of minimally invasive rapid deployment versus conventional full sternotomy aortic valve replacement. *Ann Thorac Surg* 2015;99:17-25.
4. Gilmanov D, Miceli A, Ferrarini M, et al. Aortic valve replacement through right anterior minithoracotomy: can sutureless technology improve clinical outcomes? *Ann Thorac Surg* 2014;98:1585-92.

5. Shrestha M, Folliguet TA, Pfeiffer S, et al. Aortic valve replacement and concomitant procedures with the Perceval valve: results of European trials. *Ann Thorac Surg* 2014;98:1294-300.
6. Borger MA, Dohmen P, Misfeld M, et al. Minimal invasive implantation of an EDWARDS INTUITY rapid deployment aortic valve. *Multimed Man Cardiothorac Surg* 2013;2013:mmt011.
7. Phan K, Tsai YC, Niranjana N, et al. Sutureless aortic valve replacement: a systematic review and meta-analysis. *Ann Cardiothorac Surg* 2015;4:100-11.
8. Haverich A, Wahlers TC, Borger MA, et al. Three-year hemodynamic performance, left ventricular mass regression, and prosthetic-patient mismatch after rapid deployment aortic valve replacement in 287 patients. *J Thorac Cardiovasc Surg* 2014;148:2854-60.

Cite this article as: Misfeld M. Minimally invasive aortic valve replacement using the Perceval S sutureless valve. *Ann Cardiothorac Surg* 2015;4(2):203-205. doi: 10.3978/j.issn.2225-319X.2015.02.07