

Emergent treatment of aortic rupture in acute type B dissection

Santi Trimarchi, Sara Segreti, Viviana Grassi, Chiara Lomazzi, Carlo de Vincentiis, Vincenzo Rampoldi

Thoracic Aortic Research Center, Cardiovascular Surgery, Policlinico San Donato IRCCS, Milan, Italy

Correspondence to: Santi Trimarchi, MD, PhD. Thoracic Aortic Research Center, Policlinico San Donato IRCCS, University of Milano, Via Morandi, 30, 20097 San Donato Milanese MI, Italy. Email: Santi.trimarchi@unimi.it or satrimarchi@gmail.com or santi.trimarchi@grupposandonato.it.

Massive left hemothorax is a rare and dramatic complication of acute type B aortic dissection. The primary endpoint is to treat the aortic rupture, stop the bleeding and stabilize the hemodynamic status, with the aim to prevent mortality and major cardiac, cerebral, visceral and renal complications. Thoracic endovascular repair (TEVAR) is the most frequent management, although its planning, in these emergent patients, may be very difficult and sub-optimal imaging may result at post-operative examination (CT and MRI). In case of TEVAR is not the definitive treatment of the aortic disease, a second stage surgical management can be performed in elective status, in a patient with a total clinical recover. In acute and dramatic circumstances, like ruptured type B dissection, TEVAR is a valid and suitable bridge procedure to open surgery, reducing the overall risk for mortality and major complications.

Keywords: Acute type B dissection; aortic rupture; thoracic endovascular repair (TEVAR); frozen elephant trunk



Submitted Mar 21, 2014. Accepted for publication May 16, 2014.

doi: 10.3978/j.issn.2225-319X.2014.05.05

View this article at: <http://dx.doi.org/10.3978/j.issn.2225-319X.2014.05.05>

Aortic rupture with massive left hemothorax is a catastrophic complication of acute type B aortic dissection (*Figure 1*). This is associated with high mortality, due to primarily hemorrhagic shock and hypotension. In this setting, treatment is usually represented by open surgery and/or thoracic endovascular repair (TEVAR). TEVAR is currently the most frequently adopted management; however, its planning in these emergent patients may be very difficult. In emergency, important issues include: (I) presence of a proximal intimal tear in the left hemiarch and absence of useful and safe proximal aortic neck; (II) undersized aortic diameter at preoperative CT scan related to the hypotension; and (III) unavailability of the proper endograft size in that moment.

First stage-TEVAR

Clinical presentation

Hypotension: hemorrhagic shock (mean arterial pressure <50/0 mmHg, Hb <5 g/dL).

Sizing and preparation

The patient is placed in a supine position. Under general

anesthesia, right femoral artery access is achieved, and the appropriate endograft size selected (*Figure 2*).

Operation

The stent-graft is introduced with a percutaneous or cut-down technique to cover promptly the proximal entry tear and rupture (*Figure 3*).

The stent-graft is placed in the left hemi-arch, zone 2 based on the Ishimura classification, between the origin of the left common carotid artery and the origin of the left subclavian artery (LSA) (*Figure 3*).

LSA endovascular closure is performed to avoid type II endoleak (*Vascular Plug*). In emergency there's no indication to left carotid-subclavian artery bypass (*Figure 4*).

Hemothorax drainage can then be achieved via left thoracotomy (*Figure 5*).

Postoperative course

The primary endpoint is to treat the aortic rupture, stop the bleeding and stabilize the hemodynamic status, with the aim to prevent mortality and major cardiac, cerebral,

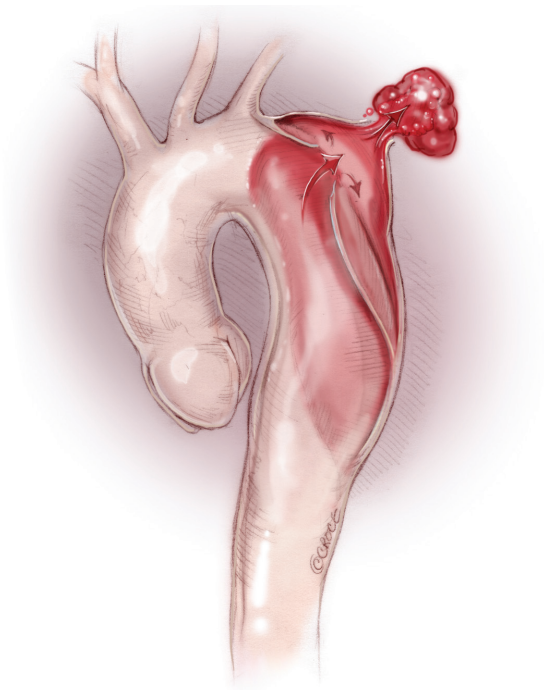


Figure 1 Ruptured acute type B dissection with massive left hemothorax.

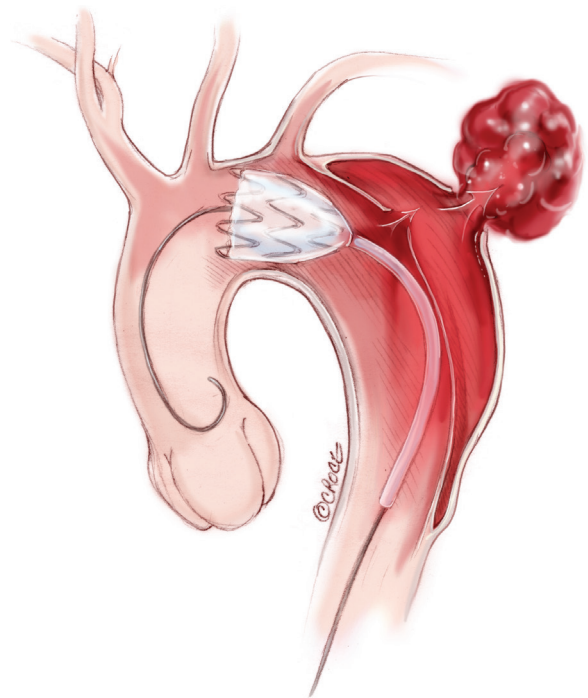


Figure 3 Endograft deployment to cover the entry tear and treat the aortic rupture.

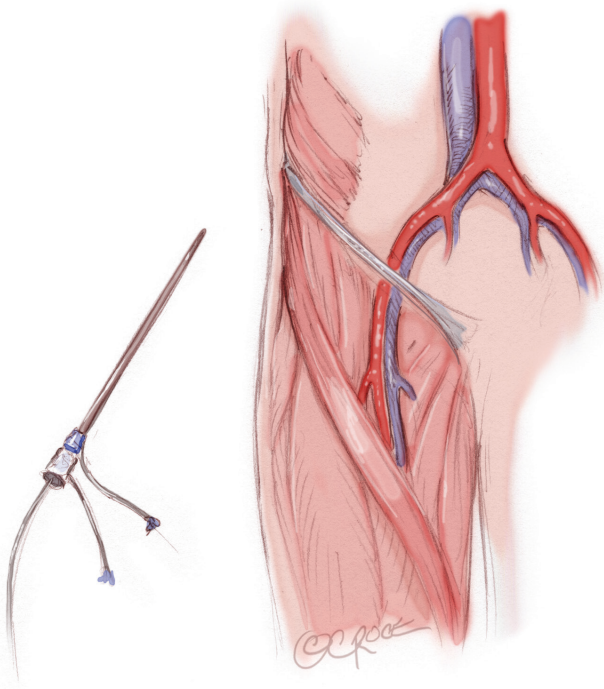


Figure 2 Percutaneous approach avoids the surgical cut-down of the femoral artery.

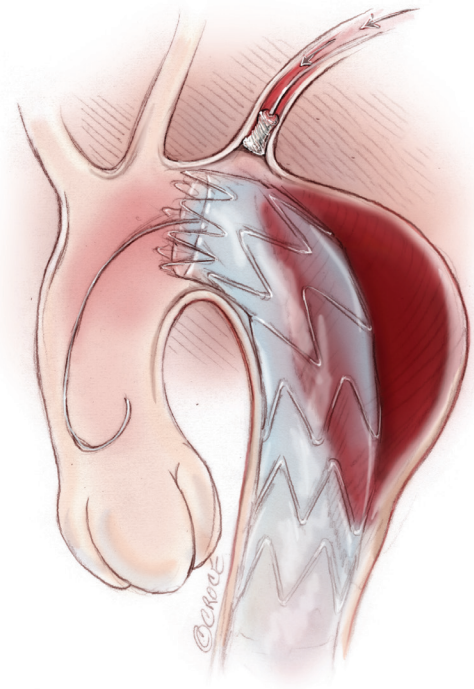


Figure 4 Vascular plug positioning to avoid type 2 endoleak from left subclavian artery.

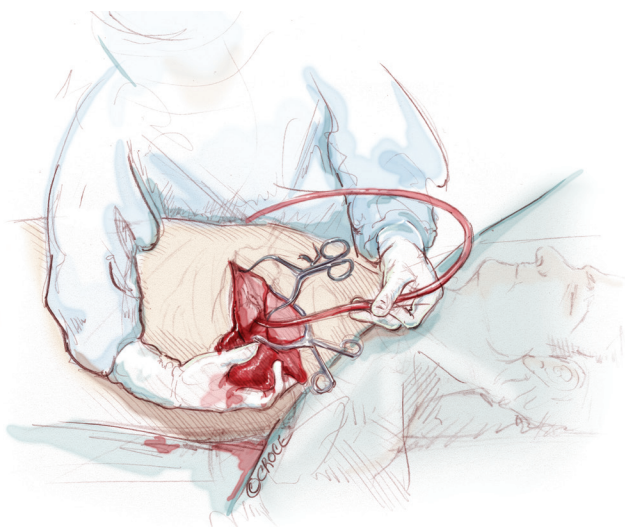


Figure 5 Massive hemothorax drainage via left thoracotomy.

visceral and renal complications. Nevertheless, sub-optimal result may be evident at post-operative examination (CT and MRI): partial apposition of the proximal segment of the endograft (bird beak), evidence of undersized endograft, presence of endoleaks (*Figure 6*).

In such cases, a second operative stage need to be planned. This is performed in a patient with a total clinical recover. In order to fix the proximal endograft in a safe and durable way, open aortic arch repair is managed. The distal arch anastomosis is sutured with the proximal tip of the stent graft.

In patients with type B aortic dissection who were already managed with TEVAR, endovascular approach includes the necessity to extend the proximal landing zone into the ascending/arch, using hybrid techniques. However, patients who suffered aortic dissection may have a fragile arch and TEVAR represents only an alternative to surgical management.

Second stage-ascending aorta and total arch replacement (frozen elephant-trunk technique)

Clinical presentation

Normotension (MAP 120/60, Hb >12 g/dL), general good condition.

Exposure and cannulation

Standard median sternotomy is done with aortic care.

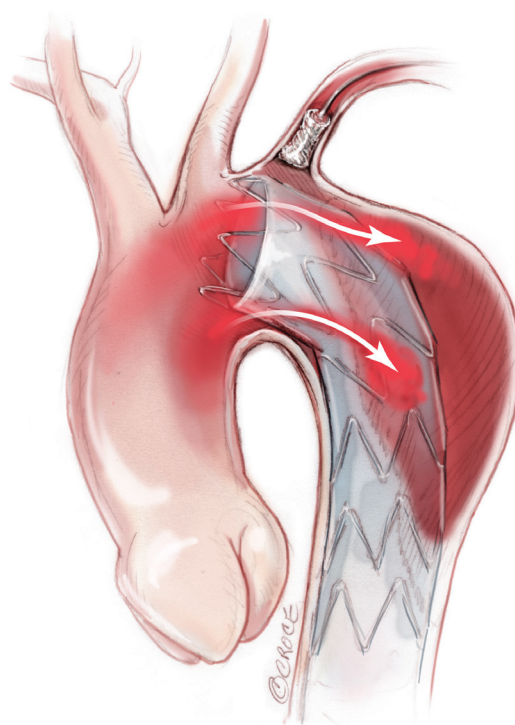


Figure 6 Partial apposition of the proximal segment of the endograft (bird beak) favoring type Ia endoleaks.

The exposure and mobilization of supra-aortic vessels is performed. The innominate vein is mobilized or ligated and divided. Intravenous heparin is administered.

The arterial cannulation is approached via ascending aorta or axillary artery. This procedure facilitates the administration of continuous antegrade cerebral perfusion during deep or moderate hypothermia.

Two staged venous cannula is placed via inferior vena cava and right atrium; left heart vent via right superior pulmonary vein. After cardiopulmonary bypass is initiated, systemic cooling is established. Circulatory arrest is performed between 22-26 °C (bladder temperature).

Bilateral cerebral near-infrared spectroscopy sensors (NIRS) are placed to monitor brain oxygenation during the procedure.

Operation

The ascending aorta and transverse aortic arch are opened. Two balloon-tipped cannulas are placed into the left common carotid artery and the innominate artery to provide selective antegrade cerebral perfusion (*Figure 7*). In case axillary arterial cannulation, right selective cerebral

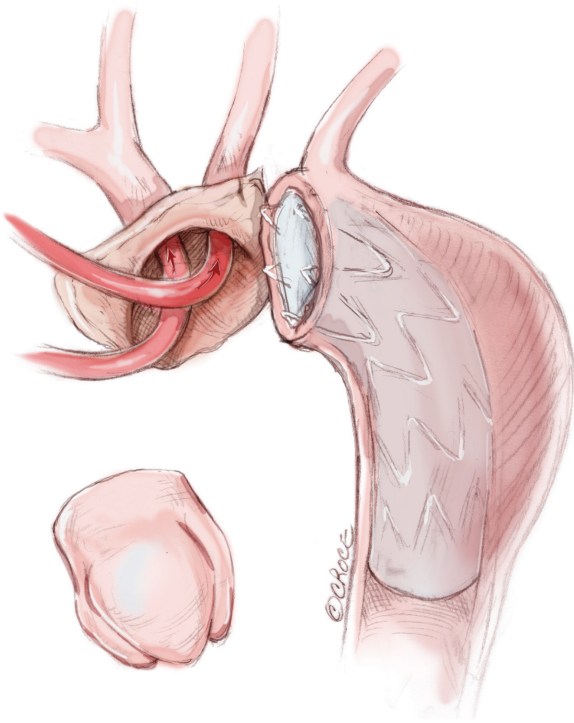


Figure 7 Opened aortic arch.

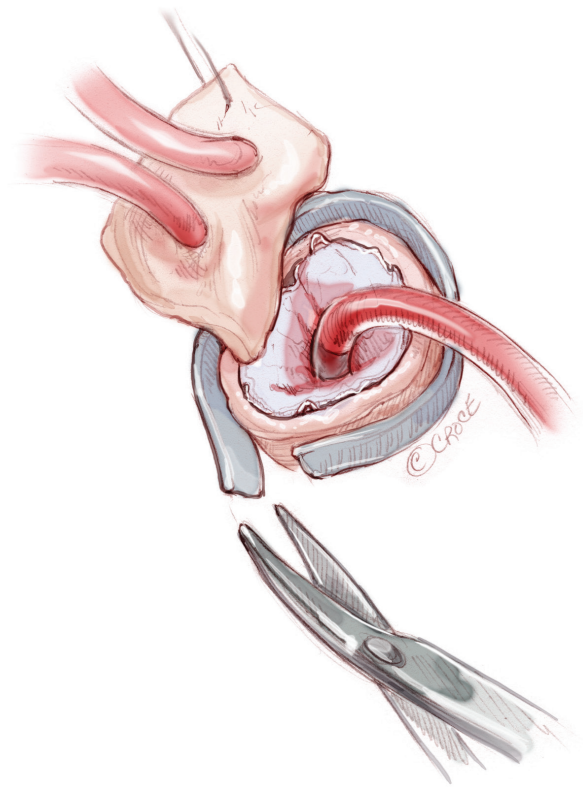


Figure 9 Outer Teflon felt positioning.

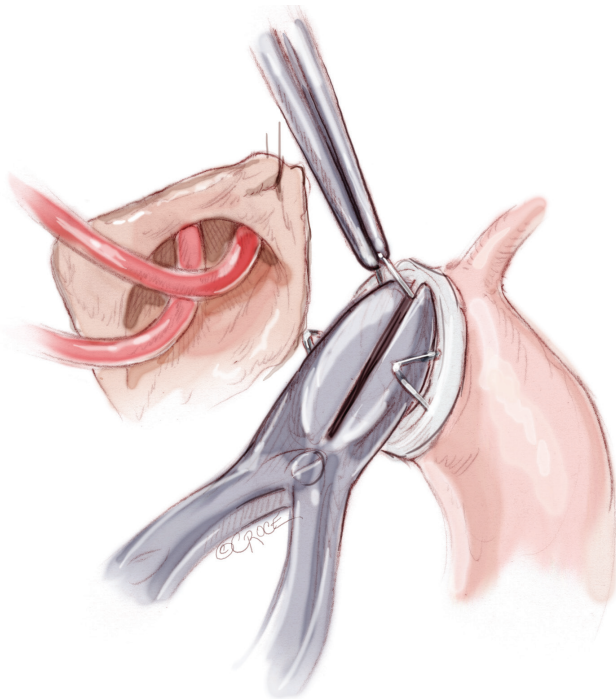


Figure 8 Stent-graft cutting.

perfusion is obtained clamping the innominate artery. A cold crystalloid cardioplegia is administered via the coronary ostia.

If present, proximal uncovered stents are cut and removed from the endograft (*Figure 8*).

Distal anastomosis is sutured between endograft and Dacron surgical graft and reinforced with outer Teflon strip (*Figure 9*). Three or four interrupted stitches with pledgets are sutured at polar points to fix the stent-graft before the continuous suture (*Figures 10,11*). When feasible, the re-implantation of the innominate artery and left carotid artery is managed with an island technique (*Figure 12*).

Surgical graft is clamped before the origin of the supra-aortic vessels and total cardiopulmonary bypass restarts re-warming the patient. The proximal ascending aorta anastomosis is then sutured.

The ascending aorta is de-aired and unclamped to restore myocardial perfusion.

After adequate re-warming, the cardiac activity is restarted by shock and the CPB is stopped when the

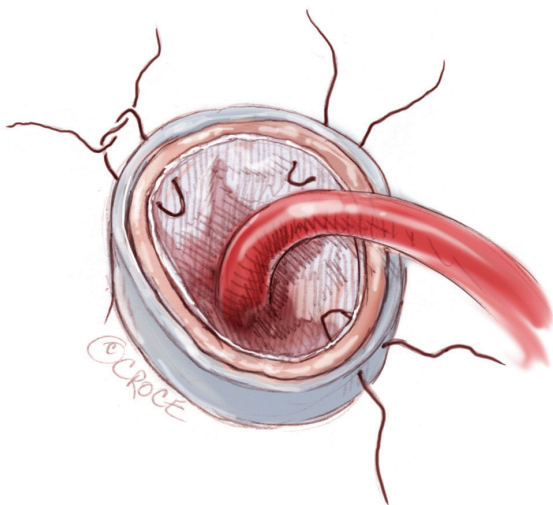


Figure 10 Endograft fixing using Teflon felt stitches.

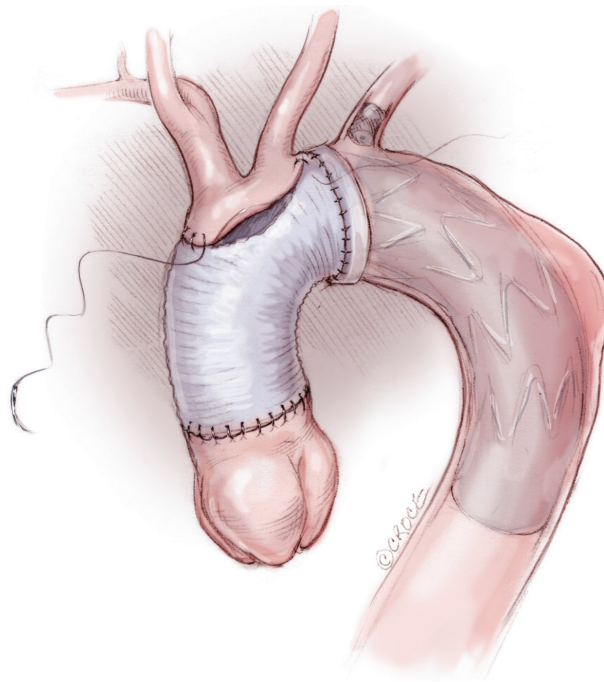


Figure 12 Island technique.

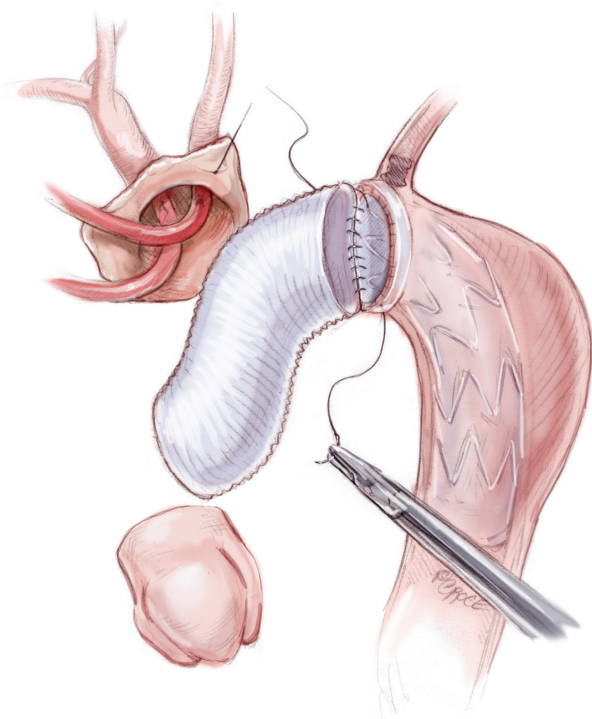


Figure 11 Distal graft-endograft anastomosis.

temperature reaches 35-36 °C. The CPB cannulas are removed. Atrial and ventricular temporary pacemaker and drainage tubes are placed. Accurate hemostasis and sternal

closure are performed at the end of the intervention.

Comments

Ruptured acute type B dissection presenting with hemodynamic instability or shock condition have poor outcome. In this setting, the primary aim is to control the aortic bleeding preventing mortality and major morbidity. The possibility to treat such catastrophic event with endovascular procedures allowed to obtain better in-hospital results compared to open surgery. However planning TEVAR in emergency setting can face with important issues like presence of proximal intimal tear in the left hemiarch and absence of useful and safe proximal aortic neck, undersized aortic diameter at preoperative CT scan related to the hypotension and unavailability of the proper endograft size in that moment.

In some cases, TEVAR represents both the resolution of the acute status and the definitive treatment of the aortic disease.

In other patients, TEVAR can be associated with suboptimal image results, although it is able to stabilize

the hemodynamic status, permitting a temporary patient recover. In this situation TEVAR represents the first step of the aortic treatment. The following second stage consists of an open arch repair procedure, that is safer managed in elective status.

In acute and dramatic circumstances, like ruptured type B dissection, TEVAR is a valid and suitable bridge procedure

to open surgery, reducing the overall risk for mortality and major complications.

Acknowledgements

Disclosure: The authors declare no conflict of interest.

Cite this article as: Trimarchi S, Segreti S, Lomazzi C, Grassi V, de Vincentiis C, Rampoldi V. Emergent treatment of aortic rupture in acute type B dissection. *Ann Cardiothorac Surg* 2014;3(3):319-324. doi: 10.3978/j.issn.2225-319X.2014.05.05