



Robotic mitral valve repair in National Taiwan University Hospital: 10-year results

Nai-Kwan Chou¹, Yi-Chia Wang², Chi-Hsiang Huang², Nai-Hsin Chi¹

¹Division of Cardiovascular Surgery, Department of Surgery, National Taiwan University Hospital, Taipei, Taiwan; ²Department of Anesthesiology, National Taiwan University Hospital, Taipei, Taiwan

Correspondence to: Nai-Hsin Chi, MD. No. 7, Chung Shan S. Rd., Zhongzheng Dist., Taipei City 10002, Taiwan. Email: chinaihsin@gmail.com.

Background: With the help of robotic surgical systems and their 3-dimensional, high-resolution imaging, mitral repair with long shaft instruments and endo-wrist functionality has become a feasible reality. Patients benefit from maintained thoracic cage integrity, reduced surgical trauma, and faster return to normal functional activity. We describe National Taiwan University Hospital's 10-year experience with robotic-assisted mitral valve repair procedures for repairing mitral regurgitation.

Methods: We performed a retrospective observational cohort study of patients undergoing robotic-assisted mitral valve repair for severe mitral regurgitation at National Taiwan University Hospital. Between January 2012 and September 2022, 450 consecutive patients underwent robotic mitral valve repair with or without additional cardiac procedures. All procedures were completed by a single surgical team.

Results: Four hundred and fifty patients, with 272 (60.4%) isolated mitral repairs and 178 (39.6%) combined additional (one or more) cardiac procedures were performed. The Euroscore II estimate mortality was 3.1%±2.7%. The average cardiopulmonary bypass (CPB) time was 124±42 minutes, and the average operation time was 165±51 minutes. Perioperative and 30-day mortality was observed in one (0.22%) patient. Mean intensive care unit stay was 26.5±26.0 hours. Postoperative stroke was observed in one (0.22%) patient and new-onset atrial fibrillation was observed in 71 (15.78%) patients. All patients were in less than mild mitral regurgitation and 422 (93.78%) had none or trace regurgitation at discharge. Freedom from moderate mitral regurgitation was 97.6%, and freedom from mitral valve reoperation was 98% at 10 years.

Conclusions: With standardized robotic procedures and non-compromised repair techniques, excellent short-term outcomes and long-term valve repair durability can be achieved in experienced centers.

Keywords: Robotic mitral repair; mitral repair; robotic cardiac surgery; robotic surgery



Submitted Oct 26, 2022. Accepted for publication Nov 18, 2022.

doi: 10.21037/acs-2022-rmvs-29

View this article at: <https://dx.doi.org/10.21037/acs-2022-rmvs-29>

Introduction

Minimally invasive surgery in mitral valve disease is ultimately done to increase the benefit to the patient, principally, to reduce surgical trauma and obtain better post-operative results. Totally endoscopic, robotic-assisted approaches have become increasingly popular for surgeons in treating mitral valve disease. Surgeons tend to use the da Vinci system (Intuitive Surgical, CA, USA) completely endoscopically, as the console is remote from the patient. The 3-dimensional, high-resolution imaging provided by

the robotic endoscope not only magnifies the surgical field, but also extends the operator's vision around the submitral apparatus (1-3). The robotic arm system with functional wrist inputs and tremor-steady motion mitigation makes the surgery far more accurate and precise. With the help of robotic inputs, the patients can maintain thoracic cage integrity, reduce surgical trauma, and return to normal functional activity faster (1-5). We describe the National Taiwan University Hospital's 10-year experience with totally endoscopic, robotic-assisted mitral valve repair procedures for severe mitral regurgitation.




Figure 1 Ports location and settings of operation room. (A) Port location. The 3 cm working port is located in the 4th intercostal space with a soft tissue protector. Tissue protector (black arrow). The right arm is in the 6th intercostal space (red arrow) at right anterior axillary line, left arm is in the 3rd intercostal space (yellow arrow). Left atrial retractor port is in the 4th intercostal space (white arrow) between working port and sternal margin. (B) Overview of robotic setting. The whole view of robotic arms machine docking and the cardiopulmonary bypass machine is on the right side of the picture, the trans-esophageal echocardiography is located in the left side of the picture.

Methods

We performed a retrospective observational cohort study of patients undergoing totally endoscopic, robotic-assisted isolated or concomitant mitral valve repair for severe mitral regurgitation at National Taiwan University Hospital. Between January 2012 and September 2022, 450 consecutive patients underwent robotic mitral valve repair, among them 272 (60.4%) were isolated mitral repair and combined additional (one or more) cardiac procedures were performed in 178 (39.6%) patients. Additional procedures included: ablation for atrial fibrillation, left atrial appendage closure, tricuspid valve repair, patent foramen ovale closure, atrial septal defect closure, left atrial thrombectomy, septal myectomy for hypertrophic obstructive cardiomyopathy and aortic valve replacement. There were 166 (36.9%) patients with atrial fibrillation pre-operatively and combined ablation surgery was performed in 136 (81.9%) of them. All procedures were completed by a single surgical team with da Vinci Si and Xi Robotic Systems. We excluded patients undergoing mitral valve replacement due to rheumatic valve disease, heavily calcified leaflets, and those who decided to those who decided to have their valve replaced preoperatively.

Surgical techniques

All patients were screened with computed tomography scans for peripheral bypass feasibility. If there was strong evidence of iliac artery calcification, stenosis, and/or a porcelain aorta, then the patient would be excluded from minimally invasive surgery. In a patient older than 55 years, or one with one with calcification of their coronary arteries on

computed tomography, then coronary artery angiography will be performed (6,7). Peripheral cannulation was mostly performed using the right groin. Our setup for peripheral cannulation has been described previously. In half of the patients, the right common femoral artery was cannulated percutaneously under ultrasound guidance. Two Proglide suture systems were used for the arterial cannulation. In the other group of patients, the femoral artery was exposed with a 2 cm transverse incision over the groin and direct cannulation completed. For venous cannulation, the right jugular and right femoral veins were utilized. A 15-Fr venous cannula was introduced in the jugular vein; 21–25 Fr venous cannulae were used for femoral vein cannulation, with all procedures monitored under ultrasound and transesophageal echocardiography guidance (7-9).

Our operative set-up has been described previously. In brief, we used single lumen endotracheal intubation for airway security, and following the anesthetic preparation, a 3 cm mini-thoracotomy, at the right 4th intercostal space was performed. We used soft tissue protectors to expose the port without adopting any rib retractors. Usually, the 3rd and 6th intercostal spaces were used for the insertion of left and right working ports respectively (*Figure 1A,1B*). After cardiopulmonary bypass (CPB) is initiated, the pericardium was opened and we used a long shaft cardioplegic needle on the aortic root and the detachable Glauber clamp was inserted through the working port into the thoracic cage (10).

Mitral valve repair techniques

All the patients selected with severe, symptomatic mitral regurgitation underwent transthoracic echocardiography

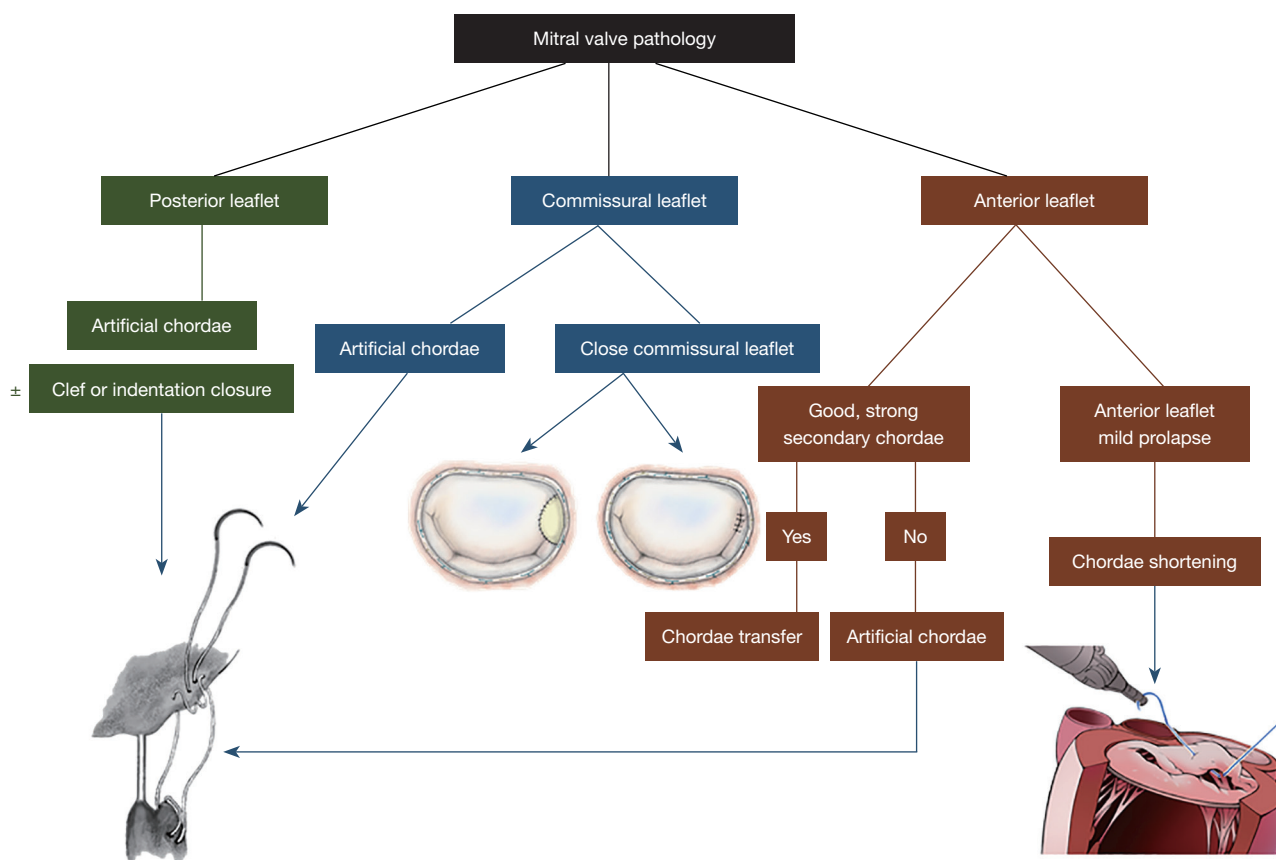


Figure 2 Mitral valve repair techniques. We use anatomical lesion sets to determine repair strategy. Before an operation, the lesion should be determined by echocardiography. The repair techniques are adopted according to the lesion location. Artificial chords are used in the prolapsed posterior leaflet and anterior leaflet without good secondary chordae for transferring. Chordae shortening techniques are adopted to shorten the elongated chords in the leaflet margin.

and intra-operative transesophageal echocardiography to determine the lesion site. The repair techniques were dependent on the lesion location, and different repair strategies were selected using our repair algorithm (Figures 2,3). We standardized the preparing and robotic platform steps, along with mitral repair strategies to ensure stable outcomes.

Posterior leaflet (Figure 2)

When the lesion is on the posterior leaflet, most of the time, we use artificial chords to secure the prolapsed leaflet and the papillary muscle using 4-0 Gore-Tex sutures. The length of the artificial chord is determined by the annulus height and is adjusted during a saline test. Any indentation or clefts are closed to ensure a smooth coaptation zone and provide long-term durability.

Commissural leaflet (Figure 2)

If the lesion is around the commissural area, the commissure will be closed by edge-to-edge stitches between nearby anterior and posterior leaflets, or with a magic stitch. If the lesion involves the annulus around the commissure, a patch repair will be adopted to close the commissure and maintain the annulus morphology.

Anterior leaflet (Figure 2)

In the anterior leaflet, there are three scenarios. First, anterior leaflet prolapse where healthy and strong secondary chords exist—in this condition we will perform chordae transfer. Second, anterior leaflet chordae rupture or prolapse without healthy secondary chords—here we will use artificial chords on the anterior leaflet. The adjustment

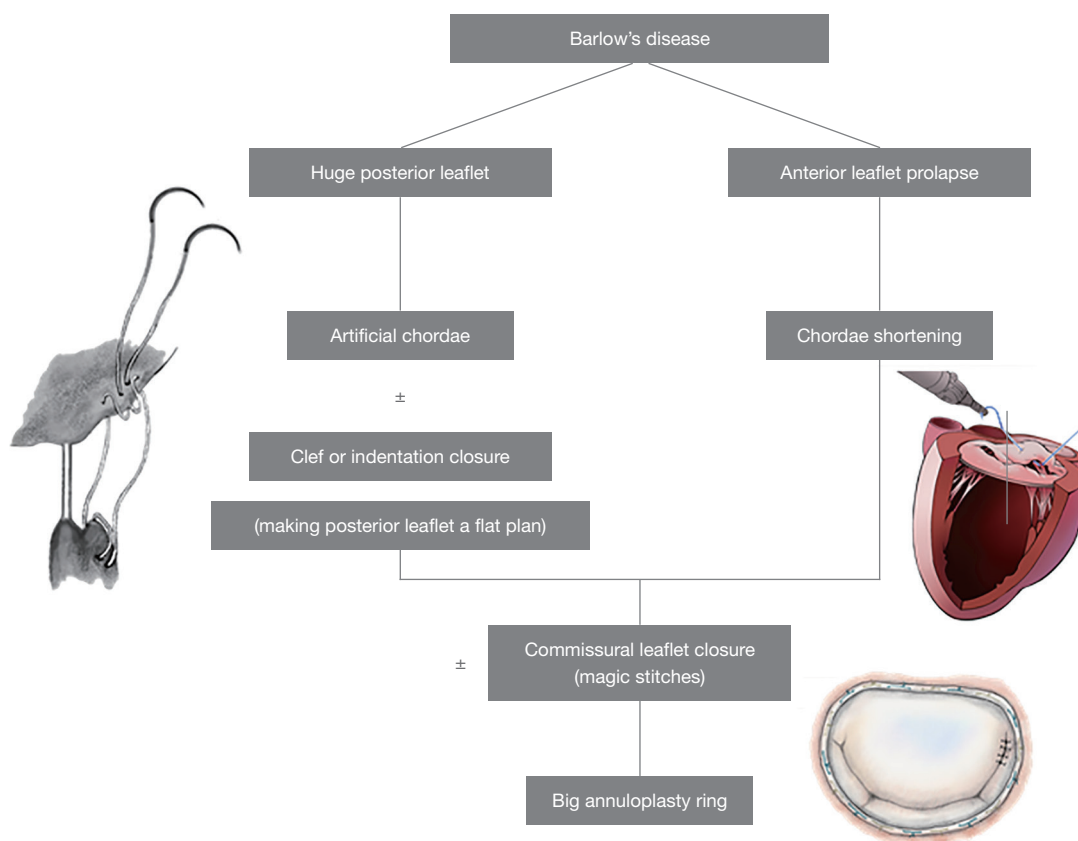


Figure 3 Mitral valve repair techniques in Barlow's disease. The repair strategy for Barlow's disease is a combination of all techniques described according to the lesion set. With huge prolapsed redundant posterior leaflets, we use artificial chords to relocate to the annular plane and close all indentations and clefts to make for good coaptation. The anterior leaflets are shortened if necessary, followed by commissural closure and annuloplasty ring fixation.

of the chord length on the anterior leaflet is dependent on the annulus height and is adjusted during a saline test. Third, if the anterior leaflet has mild prolapse, sometimes called pseudo-prolapse, then we will be using a chordae shortening method to shorten the chordae by 2–3 mm on the leaflet side.

Barlow's disease (Figure 3)

Barlow's disease requires a combination of the techniques from every lesion site (Figure 2). The techniques applied are listed on Figure 2.

Annuloplasty ring

All of the degenerative and secondary mitral regurgitation cases will require the annulus to be secured by whole ring

annuloplasty. We use standard interrupted braded polyester sutures on the annulus. All the degenerative mitral repair cases are completed using true-sized annuloplasty rings, and the secondary mitral valves are completed using down-sized rings. The ring is secured either using knot pusher or knot tightening devices.

Robotic instruments

On the robotic right arm, we use monopolar curved scissors for cutting and coagulation, a large SutureCut needle driver when suturing with cutting functionality that permits surgeons to cut the suture whenever necessary without changing instruments. On the left arm, we routinely use DeBakey forceps. The atrial retractor we use is a short right-sided atrial retractor to elevate the left atrium and explore the mitral valve.

Table 1 Demographic and operative data

Variables	N=450
Age (years)	56.8±17.5
Male gender	279 (62.0%)
NYHA class I–II	291 (64.7%)
NYHA class III–IV	159 (35.3%)
BSA	1.87±0.22
Diabetes mellitus	126 (28.0%)
Hypertension	135 (30.0%)
Chronic obstructive pulmonary disease	32 (7.1%)
Peripheral artery disease	0 (0%)
Cerebrovascular disease	8 (1.7%)
Atrial fibrillation	166 (36.9%)
LVEF ≤50%	12 (10.3%)
EuroScore II	3.1±2.7
Cardiac procedure	
Isolated valve repair	272 (60.4%)
Valve repair + combined AF ablation	136 (30.2%)
Mitral combine tricuspid repair	52 (11.5%)
Mitral combine ASD or PFO closure	12 (2.7%)
Mitral repair combines aortic valve replacement	5 (1.1%)
Mitral valve lesion location	
Posterior	167 (37.1%)
Anterior	92 (20.4%)
Combine	70 (15.6%)
Commissure	69 (15.3%)
Barlow's disease	41 (9.1%)
Secondary	11 (2.4%)

Data are expressed as mean ± standard deviation or number (%). NYHA, New York Heart Association; BSA, body surface area; LVEF, left ventricular ejection fraction; AF, atrial fibrillation; ASD, atrial septal defect; PFO, patent foramen ovale.

Data collection & statistical analysis

Perioperative variables, demographics and early clinical outcomes were prospectively recorded. Categorical parameters are presented as counts and percentages, whilst continuous parameters are presented as mean ± standard deviation.

Results

The Euroscore II estimate mortality was 3.1%±2.7%. The mitral valve lesion was located in the posterior leaflet in 167 patients, anterior in 92, combined in 70, commissural in 69, and Barlow's disease in 41 (*Table 1*).

Learning curve

The robotic learning curve was demonstrated by the operation time and CPB time in the first consecutive 30 isolated mitral valve repair cases (*Figure 4*). Initially the operation time, bypass time and console time were more than 350 minutes, but within 10 cases, the procedure time can be reduced a reasonable amount. The average CPB time was 124±42 minutes, and the average operation time was 165±51 minutes. Mean intensive care unit stay time was 26.5±26.0 hours. Postoperative stroke was observed in one (0.22%) patient and new-onset atrial fibrillation was observed in 71 (15.78%) patients. Perioperative and 30-day mortality was observed in one (0.22%) patient. All patients were in less than moderate mitral regurgitation and 422 (93.78%) had none or trace regurgitation at discharge. Postoperative clinical outcome data are presented in *Table 2*. Freedom from moderate mitral regurgitation was 97.6% at 10 years (*Figure 5*), and freedom from reoperation for the mitral valve was 98%; 9 patients required a re-do mitral valve surgery, 3 because of severe mitral regurgitation reappearance, 4 because of symptomatic hemolytic anemia due to mitral regurgitation and 2 because of repeated infective endocarditis.

Discussion

In this study, we have explored the outcomes of 450 mitral valve repairs from 2012 to 2022, a program set up and operated by a single experience team. The learning curve can be shortened after establishing a standardized robotic protocol (*Figure 4*). With the standardized protocol, all the team members know what to do at every step, allowing for the operation and CPB time to be well-controlled within 10 isolated mitral valve repair cases. Our average operation time for mitral repair was 165±51 minutes, which is reasonable in mitral valve surgery (5,11).

As experience grows with robotic techniques and more cardiac surgeons become proficient with this innovative technology, the volume of robotic cardiac procedures around the world will increase, no doubt helped along by the introduction of new robotic systems and patient

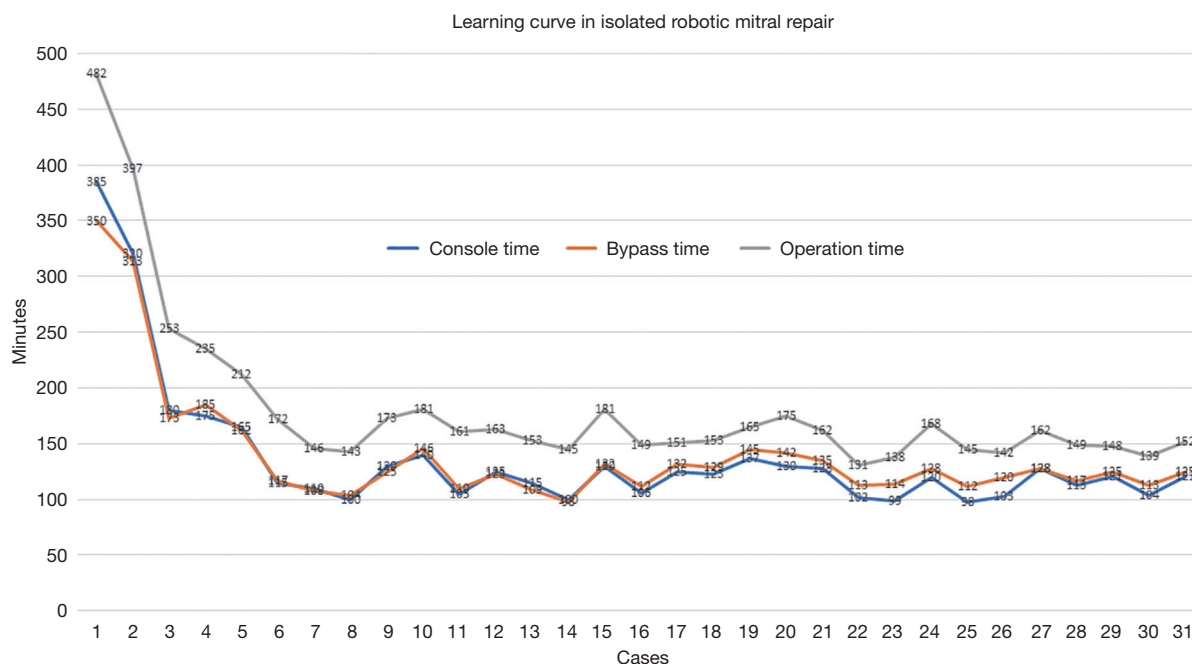


Figure 4 Console time, operation time, cardiopulmonary bypass time in the first 30 isolated mitral valve repair patients. In the first operation, the surgical time was more than 450 minutes and console time was 385 minutes. With continuous efforts on standard steps and team setup, the operation time can be less than 200 minutes in less than 10 isolated mitral valve repair cases.

demand (12-14). In this single team, pre-operative intention to repair the mitral valve is determined by valve pathology. In those with degenerative valve disease and treatable secondary mitral regurgitation patients, after shared decision making with patients, the repair rate was 100%. We excluded those with rheumatic mitral disease and calcified leaflets with mitral stenosis. In advanced, experienced teams like Loulmet, the mitral repair boundaries can be extended in severe calcification, but this is not routine in our center (11,15). We also excluded infected endocarditis with destroyed leaflets of more than half of the portion of the posterior leaflet, or more than 1/3 of anterior leaflet. Those patients received robotic mitral valve replacements.

Patient selection

Patient selection is very important, but never more so than in the beginning of a robotic program. We do not use peripheral bypass in patients with iliac artery stenosis, or those with dense pleural adhesions. Those with unsuitable peripheral bypass conditions, severe mitral annular calcification, more than moderate aortic regurgitation, poor ventricular function and high pulmonary artery pressures,

will not be selected in the early phase of a program. After 1–2 years of maturation of the team, we will operate under more complex conditions. Our cohort had very good short-term post-operative outcomes. With proper screening and selection of patients, short-term surgical outcomes can be comparable to, or even better than sternotomy (13,16).

Perioperative outcomes

Experienced groups have now reported on thousands of patients collectively who have undergone robotic-assisted mitral repair, with a hospital mortality rate of less than 0.9%, stroke rate of 0.6% to 1.7%, re-exploration for bleeding of 2.2% to 4.7%, and rare chest wall infections (5,11,15,17). In our experience, the conversion rate was zero, and stroke and mortality rates of 0.2%. These intraoperative results stem from several key efforts.

First, adequate patient screening. We don't do robotic approaches on high-risk patients in the beginning stages of a robotic program until the whole team becomes familiar with all operative steps. Second, make standardized procedures for every step in our robotic approach, which are fixed and to be strictly followed by all members, from patient

Table 2 Postoperative outcomes	
Outcomes	N=450
Conversion	0 (0%)
Reoperation check bleeding	2 (0.44%)
Mechanical ventilation time (h)	6.5±18.4
ICU stay time (h)	19±28.0
Post-operative renal failure	0 (0%)
New onset atrial fibrillation	71 (15.78%)
Postoperative stroke	1 (0.22%)
Postoperative dialysis	0 (0%)
Reintubation	2 (0.44%)
30-day mortality	1 (0.22%)
Hospital stay (d)	7±2.9
Mitral valve condition at discharge	
None-trace	422 (93.78%)
Mild	28 (6.22%)
Moderate	0 (0%)
LVEF (%)	52.3±14.7

Data are expressed as mean ± standard deviation or number (%). ICU, intensive care unit. LVEF, left ventricular ejection fraction.

preparing, positioning, port locations, cannulation methods, pericardial opening, clamping aorta, valve exposure and even techniques for valve repair. The standardized steps avoid complications encountered during minimal invasive surgery. Third, team debriefing for every surgery in the beginning stage. In this early stage, we analyzed the videos and debriefings of team members, which helped the team to build up more secure, safe and efficient surgical steps. Fourth, all the robotic cardiac surgeries are performed by the same experience team. Even with the good intra-operative results, the mean hospital stay was 7 days, which is longer than in the experienced centers throughout the United States (5,11). That is likely due in part to the health care system in Taiwan, which is a government paid insurance system—the system pays all the admission fees for 30 days after surgery, allowing for longer patient admissions in the general ward until they feel comfortable and then discharged home. We had 2 patients who needed re-checks for bleeding, one from the port site, and the other due to cardioplegic needle aortic root bleeding, all of which can be fixed by thoracoscopic approaches without extending

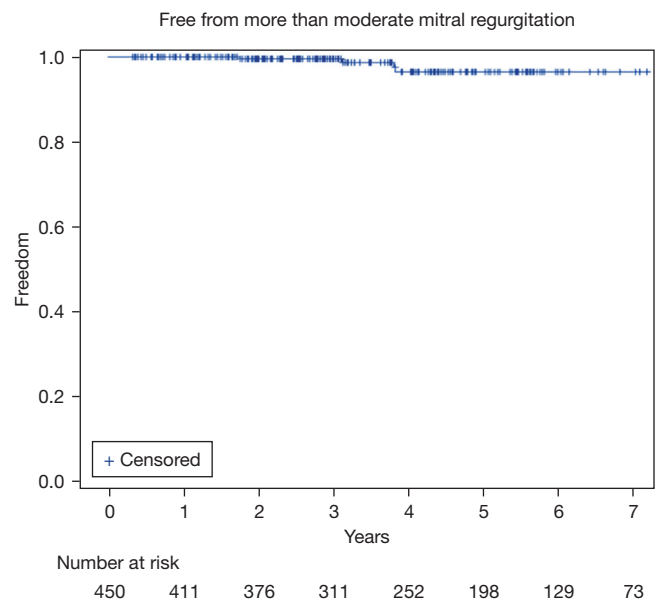


Figure 5 Freedom from more than moderate mitral regurgitation.

the wound. In the literature, the most common indications for conversion included bleeding, inadequate exposure, patient anatomy, and unsatisfactory repair (12-14). Using standardized techniques, the port location is fixed, and exposure of the mitral valve will not be a problem.

Long-term outcomes and repair durability

We used different mitral valve repair techniques for different mitral leaflet pathologies (Figures 2,3). These techniques were used in all mitral valve repair patients, not only in robotic, but also in conventional repairs for more than 20 years in our center. These can ensure the valve repair feasibility and good repair outcomes. Long-term freedom from re-operation at 10 years was 98% after robotic mitral repair. Ten-year freedom from more than moderate mitral regurgitation in all repair patients was 97.6%. All the repaired valves were secure with full ring annuloplasty using interrupted polyester sutures, which has been established and proved to have long-term durability. Every technique we applied for robotic mitral repair is the same as with a conventional approach, we never compromised on the procedure.

Despite favorable outcomes associated with robotic MV surgery, concerns about procedural safety and cost have limited its acceptance. Patients can obviously benefit from totally endoscopic robotic-assisted approaches given

maintenance of thoracic cage integrity, and should have better functional recovery. The procedural safety can be improved upon by training, practice and standardized protocols (18,19). An experienced team setup is important. The team approach should involve all the members in the operation room, CPB technicians, anesthesiologist, nurses, and cardiac surgeons. Everyone should work at the same pace and know every step (6). Training is a basic essential, as robotic instrument control is new for most surgeons. To be familiar how to handle the robotic instruments and understand the limits of the machine requires time and continuous practice. Those efforts can shorten the learning curve and achieve procedural safety.

Conclusions

In conclusion, in an experienced center, excellent short-term outcomes can be obtained in the treatment of severe mitral regurgitation with a totally endoscopic, robotic-assisted approach. The long-term durability of robotic mitral repair can also be achieved by using established valve repair techniques.

Acknowledgments

Funding: None.

Footnote

Conflicts of Interest: The authors have no conflicts of interest to declare.

Open Access Statement: This is an Open Access article distributed in accordance with the Creative Commons Attribution-NonCommercial-NoDerivs 4.0 International License (CC BY-NC-ND 4.0), which permits the non-commercial replication and distribution of the article with the strict proviso that no changes or edits are made and the original work is properly cited (including links to both the formal publication through the relevant DOI and the license). See: <https://creativecommons.org/licenses/by-nc-nd/4.0/>.

References

1. Chitwood WR Jr. Robotic mitral valve surgery: overview, methodology, results, and perspective. *Ann Cardiothorac Surg* 2016;5:544-55.
2. Chitwood WR Jr. Robotic Mitral Valve Repair: How I Teach It. *Ann Thorac Surg* 2019;107:1297-301.
3. Javadikasgari H, Suri RM, Gillinov AM. Robotic mitral valve repair: algorithmic approach in degenerative mitral valve disease. *Ann Cardiothorac Surg* 2016;5:586-8.
4. Coyan G, Wei LM, Althouse A, et al. Robotic mitral valve operations by experienced surgeons are cost-neutral and durable at 1 year. *J Thorac Cardiovasc Surg* 2018;156:1040-7.
5. Suri RM, Dearani JA, Mihaljevic T, et al. Mitral valve repair using robotic technology: Safe, effective, and durable. *J Thorac Cardiovasc Surg* 2016;151:1450-4.
6. Ishii H, Ting M, Chi NH. Robotic mitral valve repair: standardized repair strategy ensures consistent results. *Ann Cardiothorac Surg* 2018;7:837-8.
7. Chou NK, Okano R, Tedoriya T, et al. Robotic Transmitral Approach for Hypertrophic Cardiomyopathy With Systolic Anterior Motion. *Circ J* 2018;82:2761-6.
8. Chi NH, Huang CH, Huang SC, et al. Robotic mitral valve repair in infective endocarditis. *J Thorac Dis* 2014;6:56-60.
9. Wang YC, Chi NH, Wang YC, et al. Retrograde arterial perfusion and its outcome in robotic mitral-valve surgery. *Asian J Surg* 2022;45:1849-54.
10. Chi NH, Fu HY, Yu HY, et al. Comparison of robotic and conventional sternotomy in redo mitral valve surgery. *J Formos Med Assoc* 2022;121:395-401.
11. Loulmet DF, Ranganath NK, Neragi-Miandoab S, et al. Advanced experience allows robotic mitral valve repair in the presence of extensive mitral annular calcification. *J Thorac Cardiovasc Surg* 2019. [Epub ahead of print]. pii: S0022-5223(19)32405-5. doi: 10.1016/j.jtcvs.2019.10.099.
12. Goodman A, Koprivanac M, Kelava M, et al. Robotic Mitral Valve Repair: The Learning Curve. *Innovations (Phila)* 2017;12:390-7.
13. Gillinov AM, Mihaljevic T, Javadikasgari H, et al. Early results of robotically assisted mitral valve surgery: Analysis of the first 1000 cases. *J Thorac Cardiovasc Surg* 2018;155:82-91.e2.
14. Toolan C, Palmer K, Al-Rawi O, et al. Robotic mitral valve surgery: a review and tips for safely negotiating the learning curve. *J Thorac Dis* 2021;13:1971-81.
15. Loulmet DF, Koeckert MS, Neuburger PJ, et al. Robotic mitral repair for Barlow's disease with bileaflet prolapse and annular calcification using pericardial patch technique. *Ann Cardiothorac Surg* 2017;6:67-9.
16. Chemtob RA, Wierup P, Mick SL, et al. A conservative screening algorithm to determine candidacy for robotic mitral valve surgery. *J Thorac Cardiovasc Surg*

- 2022;164:1080-7.
17. Naito N, Grossi EA, Nafday HB, et al. Robotic mitral valve repair with complete excision of mitral annular calcification. *Ann Cardiothorac Surg* 2022;11:545-7.
 18. Bates MJ, Chitwood WR Jr. Minimally invasive and robotic approaches to mitral valve surgery: Transthoracic aortic crossclamping is optimal. *JTCVS Tech* 2021;10:84-8.
 19. Bonatti J, Crailsheim I, Grabenwöger M, et al. Minimally Invasive and Robotic Mitral Valve Surgery: Methods and Outcomes in a 20-Year Review. *Innovations (Phila)* 2021;16:317-26.

Cite this article as: Chou NK, Wang YC, Huang CH, Chi NH. Robotic mitral valve repair in National Taiwan University Hospital: 10-year results. *Ann Cardiothorac Surg* 2022;11(6):605-613. doi: 10.21037/acs-2022-rmvs-29