



# Two hundred robotic mitral valve repair procedures for degenerative mitral regurgitation: the Yale experience

Andrea Amabile<sup>1</sup>, Alyssa Morrison<sup>1</sup>, Michael LaLonde<sup>1</sup>, Ritu Agarwal<sup>2</sup>, Makoto Mori<sup>1</sup>, Irbaz Hameed<sup>1</sup>, Syed Usman Bin Mahmood<sup>1</sup>, Caroline Komlo<sup>1</sup>, Sigurdur Ragnarsson<sup>1</sup>, Markus Krane<sup>1</sup>, Arnar Geirsson<sup>1</sup>

<sup>1</sup>Division of Cardiac Surgery, Yale School of Medicine, New Haven, CT, USA; <sup>2</sup>Joint Data Analytics Team, Yale New Haven Health System, New Haven, CT, USA

Correspondence to: Dr. Arnar Geirsson, MD. Professor of Surgery, Division of Cardiac Surgery, Yale School of Medicine, 330 Cedar Street, New Haven, CT, USA. Email: arnar.geirsson@yale.edu.

**Background:** Robotic surgery has gained popularity over the past two decades due to the benefits related to smaller surgical incisions, enhanced technical dexterity and better intraoperative visualization. We present the Yale experience of the first two hundred totally endoscopic, robotic-assisted mitral valve repair procedures for the treatment of degenerative mitral regurgitation.

**Methods:** We performed a retrospective cohort study of patients undergoing totally endoscopic, robotic-assisted isolated or concomitant mitral valve repair for degenerative mitral regurgitation at Yale-New Haven Hospital from October 2018 to April 2022. Mitral valve repair procedures for rheumatic or secondary functional mitral regurgitation and planned robotic-assisted mitral valve replacement cases were excluded.

**Results:** Two hundred consecutive procedures were performed. The median age was 65 years (interquartile range, 58–73 years). Six patients (3.0%) had a history of mediastinal radiation, four patients (2.0%) had previous cardiac surgery, and one patient (0.5%) had cardiac dextroversion. Median cardiopulmonary bypass and aortic cross-clamp times were 122 and 79 minutes, respectively. Femoral vessel cannulation was performed percutaneously in 57 (28.5%) patients with no major access-site related complication. Aortic cross-clamping was performed with the endoaortic balloon occlusion device in 151 (75.5%) patients. No conversions to sternotomy occurred. Satisfactory repair was achieved in 100% of cases, with 184 (92.0%) and 16 (8.0%) of patients having trace/none or mild residual mitral regurgitation, respectively. Forty-two patients (21.0%) underwent concomitant Cox-maze procedure and 25 patients (12.5%) underwent concomitant tricuspid valve repair. Thirty-day mortality rate was 0.5%, with an observed-to-expected ratio of 0.53. Two patients (1.0%) underwent re-exploration for bleeding, one had early postoperative stroke (0.5%), five developed pneumothorax (2.5%) and two required dialysis for acute renal failure (1.0%). The median length of hospital stay was four days.

**Conclusions:** Excellent short-term outcomes can be achieved in experienced centers for the treatment of degenerative mitral regurgitation with a totally endoscopic, robotic-assisted approach.

**Keywords:** Robotic; mitral; repair; degenerative; regurgitation



Submitted Jun 07, 2022. Accepted for publication Aug 02, 2022.

doi: 10.21037/acs-2022-rmvs-73

View this article at: <https://dx.doi.org/10.21037/acs-2022-rmvs-73>

## Introduction

A quarter of mitral valve surgeries is performed with minimally invasive techniques every year (1) and the adoption of robotic-assisted approaches has become

increasingly popular due to the advantages related to smaller surgical incisions (i.e., less postoperative pain, better cosmetic result, shorter length of hospital stay, and more rapid return to a better level of functional activity) (2,3). In this frame, the positive role of mitral valve repair for the

surgical treatment of degenerative mitral regurgitation has been extensively validated in the literature, with a strong correlation between surgeon-level volume and clinical outcomes (4). Additionally, the adoption of a robotic platform allows for enhanced technical dexterity as well as magnified, three-dimensional visualization of the mitral valve apparatus (5-7).

We describe the Yale experience with the first 200 totally endoscopic, robotic-assisted mitral valve repair procedures for the treatment of degenerative mitral regurgitation.

## Methods

### Study design

We performed a retrospective observational cohort study of patients undergoing totally endoscopic, robotic-assisted isolated or concomitant mitral valve repair for primary (degenerative) mitral regurgitation at Yale-New Haven Hospital. We included all patients from the inception of our robotic program (October 29, 2018) to the latest available information (April 4, 2022). We excluded patients undergoing robotic-assisted mitral valve repair for rheumatic or secondary (functional) mitral regurgitation, patients undergoing planned robotic-assisted mitral valve replacement, atrial septal defect repair, primary tricuspid valve repair and resection of intracardiac primary tumors (myxoma or fibroelastoma). The Yale robotic cardiac surgery database was linked to our institutional Society of Thoracic Surgeons (STS) database, and information on demographics, comorbidities, intraoperative variables, and thirty-day outcomes was retrieved. Additional data were obtained by reviewing electronic medical records.

### Statistical analysis

Continuous variables were expressed as mean (standard deviation) or median [interquartile range (IQR)] values, based on normality of distribution which was assessed with the Kolmogorov-Smirnov test. Categorical variables were expressed as absolute and relative frequencies. Data was stored and analyzed with the Research Electronic Data Capture (REDCap) data management platform (v. 12.0.25, Vanderbilt University, Nashville, TN, USA) and Microsoft Excel (Microsoft Corporation, Redmond, WA, USA). The study was approved by the Yale Institutional Review Board (ID 2000020356, approval date: 4/4/2022).

### Surgical technique

We have previously reported our surgical set-up for robotic intracardiac procedures involving the mitral valve (8). Briefly, the patient is placed supine on the operating table with a rolled towel (or a gel pad) under the right scapula and the ipsilateral arm loosely tucked, thus minimizing conflict between the shoulder and the robotic arms. Port configuration consists of the working port and camera being placed in the third intercostal space at the left anterior axillary line; the left robotic arm port placed in the second intercostal space halfway between the anterior axillary line and the midclavicular line; the right robotic arm port placed in the fifth intercostal space slightly below the anterior axillary line; and the left atrial retractor placed in the fourth intercostal space two centimeters medial to the midclavicular line. It is of importance to aim for perfect triangulation of the right and left trocars with the robotic camera and to dock the robot with great care to maximize the airspace between the arms, subsequently minimizing any conflict. Interestingly, we had the chance to perform robotic-assisted mitral valve repair in a patient with situs inversus and cardiac dextroversion, in which case we planned ports configuration in a symmetrical fashion on the left hemithorax (9).

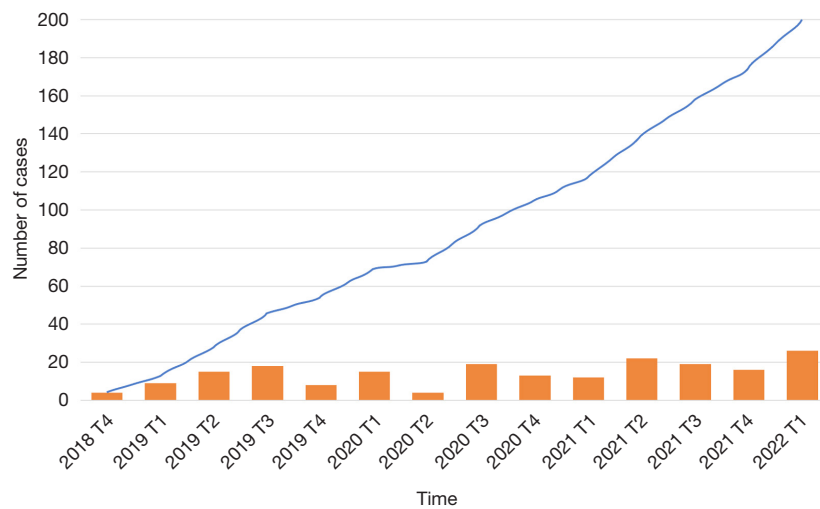
## Results

### Operative volume

The number of totally endoscopic, robotic-assisted mitral valve procedures performed at our institution for degenerative mitral regurgitation has steadily grown over time (*Figure 1*), with a temporary plateau at the second quarter of 2020 in conjunction with the first wave of the COVID-19 pandemic, which deferred nonurgent procedures nationwide (10). Nevertheless, the ratio between the number of cases performed in the first quarter of each fiscal year has been increasing over time, from a volume growth rate of +167% in 2019/2020 to +217% in 2021/2022 thus reflecting the progressive expansion in our inclusion criteria as well as the increase interest of patients and referring cardiologists.

### Demographic data

Of the 242 patients undergoing totally endoscopic, robotic-assisted cardiac surgery at our institution since the inception of our robotic program, 200 consecutive mitral valve repair



**Figure 1** Case volume over time, stratified by quarter. Columns: absolute frequency; continuous line: cumulative frequency.

procedures for degenerative mitral regurgitation were performed in the selected timespan. The median age at the time of operation was 65 years (IQR, 58–73 years), and most patients were male (58.0%). Six patients (3.0%) had a history of mediastinal radiation and four patients (2.0%) had undergone previous cardiac surgery (one with previous mitral valve repair via midline sternotomy, two with previous mitral valve repair via robotic-assisted approach, one with previous transcatheter aortic valve replacement). Mitral valve pathology included isolated posterior leaflet prolapse in 60% of patients, anterior leaflet prolapse in 11% of patients, and bileaflet prolapse in 29% of patients. The distribution of comorbidities is shown in *Table 1*.

### Intraoperative data

The median cardiopulmonary bypass and aortic cross-clamp times were 122 (IQR, 103–151) and 79 (IQR, 66–96) minutes, respectively, with a negative trend over time reflecting the operative learning curve (*Figure 2*). Details of intraoperative data are summarized in *Table 2*.

The distribution of various repair techniques stratified by localization of disease is shown in *Table 3*. Posterior and bileaflet prolapse were addressed with a combination of resection techniques (i.e., triangular resection, quadrangular resection with sliding annuloplasty) and non-resection techniques (i.e., neochordoplasty, clefts closure, commissural plication, edge-to-edge repair), as deemed appropriate at the time of intraoperative valve analysis. Notably, the proportion of patients undergoing non-resection techniques

versus resection techniques has significantly increased over time (*Figure 3*). Anterior leaflet prolapse was predominantly treated with neochordoplasty.

All patients underwent mitral valve annuloplasty, whose size distributions are shown in *Figure 4*. Forty-two patients underwent concomitant robotic-assisted Cryo-Maze for pre-existing atrial fibrillation and twenty-five patients underwent concomitant tricuspid valve repair.

Cardiopulmonary bypass was routinely performed via femoral vessels cannulation and was achieved percutaneously in 57 (28.5%) patients, who had no major access-site related complications (*Table 4*). Aortic cross-clamping was performed with the endoaortic balloon occlusion device in three-quarters of patients and with an endothoracic clamp in the remaining quarter. A second run of cardiopulmonary bypass was required in thirteen patients (6.5%), none of which required mitral valve replacement. A satisfactory repair was achieved in 100% of cases, with 92% and 8% of patients having trace/none or mild residual mitral regurgitation, respectively.

### Short-term outcomes

One patient required postoperative extracorporeal membrane oxygenation for atypical Takotsubo cardiomyopathy, eventually resulting in death. The observed thirty-day mortality rate was 0.5% across the study period, and the observed-to-expected ratio for thirty-day mortality (based on the STS predicted risk of mortality) was 0.53. Two patients (1.0%) underwent re-exploration for bleeding,

**Table 1** Demographics and preoperative variables

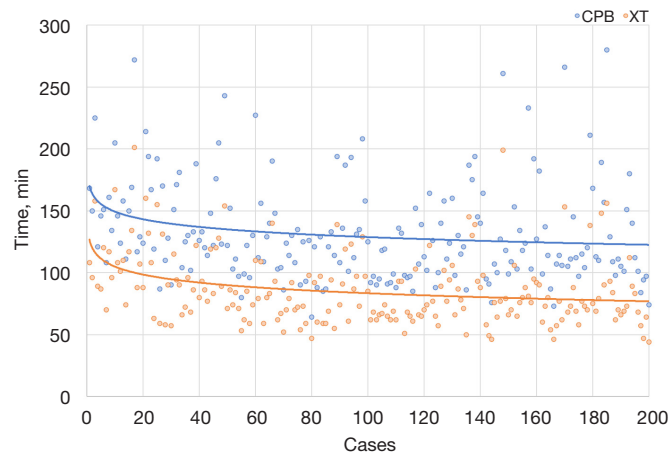
Variables	N=200
Age, years, median [range]	65 [58–73]
Female sex, n (%)	84 (42.0)
Race, n (%)	
Caucasian	174 (87.0)
African American	14 (7.0)
Hispanic/Latino	6 (3.0)
Asian	2 (1.0)
American Indian/Alaska Native	1 (0.5)
Other	3 (1.5)
Body mass index, kg/m <sup>2</sup> , median [range]	24.8 [22.7–28.6]
Hypertension, n (%)	117 (58.5)
Dyslipidemia, n (%)	43 (21.5)
Diabetes, n (%)	12 (6.0)
Family history of coronary artery disease, n (%)	15 (7.5)
Dialysis, n (%)	2 (1.0)
Infective endocarditis, n (%)	5 (2.5)
Tobacco use, n (%)	
Current, everyday	5 (2.5)
Current, some day	5 (2.5)
Former smoker	77 (38.5)
Never smoked	113 (56.5)
Chronic lung disease, n (%)	12 (6.0)
Obstructive sleep apnea syndrome, n (%)	12 (6.0)
Mediastinal radiation, n (%)	6 (3.0)
Peripheral vascular disease, n (%)	9 (4.5)
Cerebrovascular disease, n (%)	7 (3.5)
Liver disease, n (%)	9 (4.5)
Heart failure symptoms, n (%)	
NYHA class I	1 (0.5)
NYHA class II	30 (15.0)
NYHA class III	18 (9.0)
NYHA class IV	3 (1.5)
Not documented	26 (13.0)

**Table 1** (continued)

**Table 1** (continued)

Variables	N=200
History of atrial fibrillation, n (%)	54 (27.0)
Paroxysmal	13 (6.5)
Persistent	37 (18.5)
Longstanding persistent	4 (2.0)
Preoperative ejection fraction, %, median [range]	62 [58–63]
Previous cardiac surgery, n (%)	4 (2.0)
Mitral valve repair (sternotomy)	1
Mitral valve repair (robotic-assisted)	2
Transcatheter aortic valve replacement	1
Severity of mitral regurgitation, n (%)	
Severe	183 (91.5)
Moderate-to-severe	3 (1.5)
Moderate	14 (7.0)
Primary site of mitral valve disease, n (%)	
Anterior leaflet	22 (11.0)
Posterior leaflet	120 (60.0)
Bileaflet	58 (29.0)
Status, n (%)	
Elective	182 (91.0)
Semi-urgent	18 (9.0)
STS predicted scores, %, median [range]	
Mortality	0.49 [0.30–1.15]
Morbidity and mortality	5.74 [4.26–9.62]
Prolonged length of stay	1.99 [1.23–3.80]
Prolonged ventilation	2.95 [2.09–6.06]
Renal failure	0.57 [0.37–1.12]
Permanent cerebrovascular accident	0.96 [0.58–1.40]
Reoperation	2.68 [2.12–3.49]

n, number; kg, kilograms; m<sup>2</sup>, squared meters; NYHA, New York Heart Association; STS, Society of Thoracic Surgeons.



**Figure 2** Distribution of cardiopulmonary bypass and aortic cross-clamp times. Min, minutes; CPB, cardiopulmonary bypass time; XT, aortic cross-clamp time.

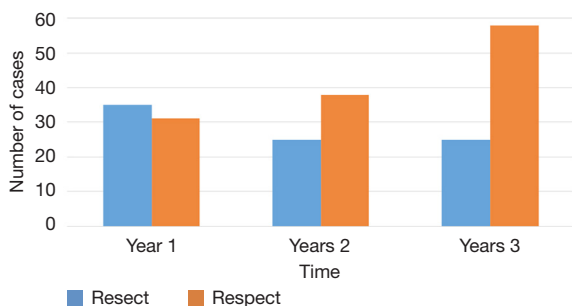
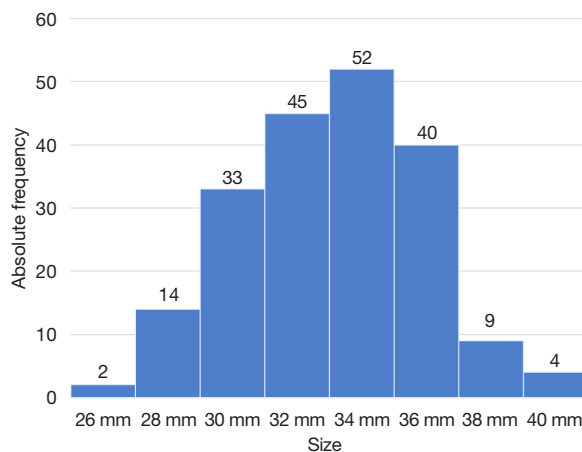
Table 2 Intraoperative variables	
Variables	N=200
Cardiopulmonary bypass time, minutes, median [range]	122 [103–151]
Aortic cross-clamp time, minutes, median [range]	79 [66–96]
Annuloplasty band size, mm, median [range]	34 [32–36]
Concomitant procedures, n	
Cryo-Maze	42
Tricuspid valve repair	25
Aortic cross-clamping strategy, n (%)	
Endothoracic clamp	49 (24.5)
Endoaortic balloon occlusion device	151 (75.5)
Second run on cardiopulmonary bypass, n (%)	13 (6.5)
Conversion to midline sternotomy, n (%)	0 (0.0)
Extubated in the operating room, n (%)	130 (65.0)
Postoperative ejection fraction, %, median [range]	60 [53–63]
Post-bypass residual mitral regurgitation, n (%)	
Severe	0 (0.0)
Moderate	0 (0.0)
Mild	16 (8.0)
Trace	89 (44.5)
None	95 (47.5)
Post-bypass mean mitral valve gradient, mmHg, median [range]	2 [2–3]

n, number; mm, millimeters; mmHg, millimeters of mercury.

**Table 3** Repair strategy stratified by localization

Repair strategy	Posterior leaflet prolapse (n=120)	Anterior leaflet prolapse (n=22)	Bileaflet prolapse (n=58)
Triangular resection, n	65	0	14
Sliding annuloplasty, n	12	0	6
Cleft closure, n	33	1	13
Commissural plication, n	7	4	11
Neochordoplasty, anterior leaflet, n	0	21	44
Neochordoplasty, posterior leaflet, n	52	0	35
Neochordoplasty, commissural, n	0	0	1
Release of secondary chordae, n	9	7	5
Edge-to-edge, n	1	0	2
Annuloplasty, n	120	22	58

n, number.

**Figure 3** Change in posterior leaflet repair techniques over time: resection (resect) versus neochordoplasty (respect).**Figure 4** Distribution of mitral valve annuloplasty band sizes. Mm, millimeters.

one patient had early postoperative stroke (0.5%), five patients developed pneumothorax (2.5%) and two patients required dialysis for acute renal failure (1.0%). In terms of airway management, 130 patients (6.05%) were extubated in the operating room and six patients (3.0%) required prolonged pulmonary ventilation beyond 24 hours. Median length of hospital stay was four days. Short-term outcomes are outlined in *Table 5*.

## Discussion

We have a relatively non-restrictive selection criteria for offering a totally endoscopic, robotic-assisted approach for mitral valve procedures. Contraindications include: (I) previous right thoracotomy or pleural decortication, due to risk of extensive intrathoracic adhesions; (II) severe mitral annular calcification, due to risk of atrioventricular groove disruption; (III) severe pectus excavatum, due to significant reduction of the anteroposterior thoracic diameter hindering the robotic working space; (IV) severe peripheral vascular disease; (V)  $\geq$  moderate aortic regurgitation; (VI) ascending aorta diameter of  $\geq 4.5$  cm. When compared to more conservative screening algorithms (11), our cohort had similar postoperative morbidity outcomes and an overall shorter length of hospital stay.

The least invasive strategy we offer to patients is percutaneous cannulation. We have previously presented its technical nuances in detail (12). Notably, the transition from open to percutaneous cannulation was associated with

**Table 4** Femoral vessels cannulation

Variables	Open cannulation (n=143)	Percutaneous cannulation (n=57)
Arterial cannula size, mm	21 [20–23]	21 [21–23]
Overall access-site related morbidity, n (%)	9 (6.3)	1 (1.8)
Hematoma formation, n (%)	4 (2.8)	1 (1.8)
Seroma formation, n (%)	2 (1.4)	0 (0.0)
Nerve injury, n (%)	1 (0.7)	0 (0.0)
Femoral artery dissection, n (%)	0 (0.0)	0 (0.0)
Access site infection, n (%)	1 (0.7)	0 (0.0)
Readmission for access site-related complication, n (%)	1 (0.7)	0 (0.0)
Need for reintervention, n (%)	0 (0.0)	0 (0.0)

mm, millimeters.

**Table 5** Postoperative morbidity

Morbidity	N=200
Reoperation for bleeding, n (%)	2 (1.0)
Postoperative stroke, n (%)	1 (0.5)
Prolonged pulmonary ventilation, n (%)	6 (3.0)
Pneumonia, n (%)	2 (1.0)
Deep venous thrombosis, n (%)	1 (0.5)
Pleural effusion, n (%)	4 (2.0)
Pneumothorax, n (%)	5 (2.5)
Renal failure, n (%)	2 (1.0)
Pacemaker implantation, n (%)	2 (1.0)
Postoperative atrial fibrillation, n (%)	48 (24.0)
Length of stay, days	4 [3–6]
30-day mortality, n (%)	1 (0.5)
30-day readmission, n (%)	27 (13.5)
Arrhythmia/heart block	12 (6.0)
Chest pain (non-cardiac)	2 (1.0)
Congestive heart failure	1 (0.5)
Mental status changes	1 (0.5)
Pericarditis	1 (0.5)
Pleural effusion requiring drainage	4 (2.0)
Other (non-cardiac-related)	6 (3.0)

a reduction in groin-related postoperative comorbidities; from 6.3% in the open femoral cannulation group to 1.8% in the percutaneous cannulation group, at no difference in terms of median arterial cannula size (21 mm in both groups).

Our cohort includes patients with history of mediastinal radiation or previous cardiac surgery, both via midline sternotomy and via robotic-assisted approach. Careful evaluation of preoperative imaging to assess the burden of intrathoracic adhesions is mandatory. Our technique for robotic-assisted adhesiolysis is based on three principles: first, dissect adhesions by staying within the surgical plane; second, perform traction and countertraction on fibrotic tissue with the aid of the tableside assistant holding a suction device; third, use previously placed sutures as landmarks of notable anatomical structures (e.g., the left atriotomy suture line to find the Waterstone's groove in redo mitral valve repairs). In our experience, two patients (1%) required exploration for postoperative bleeding and none of these belonged to the redo sub-cohort.

In conclusion, in experienced hands, excellent short-term outcomes can be achieved for the treatment of degenerative mitral regurgitation with a totally endoscopic, robotic-assisted approach and percutaneous cannulation. Follow-up studies are required to characterize mid- and long-term outcomes, as well as investigate repair durability.

## Acknowledgments

*Funding:* None.

## Footnote

*Conflicts of Interest:* MK: physician proctor and a member of the medical advisory board for JOMDD, physician proctor for Peter Duschek, speakers' honoraria from Medtronic and Terumo. AG: consulting fee for being a member of the Medtronic Strategic Surgical Advisory Board and from Edwards Lifesciences. The other authors have no conflicts of interest to declare.

*Open Access Statement:* This is an Open Access article distributed in accordance with the Creative Commons Attribution-NonCommercial-NoDerivs 4.0 International License (CC BY-NC-ND 4.0), which permits the non-commercial replication and distribution of the article with the strict proviso that no changes or edits are made and the original work is properly cited (including links to both the formal publication through the relevant DOI and the license). See: <https://creativecommons.org/licenses/by-nc-nd/4.0/>.

## References

1. Nissen AP, Miller CC 3rd, Thourani VH, et al. Less Invasive Mitral Surgery Versus Conventional Sternotomy Stratified by Mitral Pathology. *Ann Thorac Surg* 2021;111:819-27.
2. Bush B, Nifong LW, Alwair H, et al. Robotic mitral valve surgery-current status and future directions. *Ann Cardiothorac Surg* 2013;2:814-7.
3. Bonatti J, Crailsheim I, Grabenwöger M, et al. Minimally Invasive and Robotic Mitral Valve Surgery: Methods and Outcomes in a 20-Year Review. *Innovations (Phila)* 2021;16:317-26.
4. Badhwar V, Vemulapalli S, Mack MA, et al. Volume-Outcome Association of Mitral Valve Surgery in the United States. *JAMA Cardiol* 2020;5:1092-101.
5. Badhwar V, Wei LM, Geirsson A, et al. Contemporary robotic cardiac surgical training. *J Thorac Cardiovasc Surg* 2021. [Epub ahead of print]. doi: 10.1016/j.jtcvs.2021.11.005.
6. Bonatti J, Kiaii B, Alhan C, et al. The role of robotic technology in minimally invasive surgery for mitral valve disease. *Expert Rev Med Devices* 2021;18:955-70.
7. Nifong LW, Chu VF, Bailey BM, et al. Robotic mitral valve repair: experience with the da Vinci system. *Ann Thorac Surg* 2003;75:438-42; discussion 443.
8. Amabile A, Morrison A, Weinger G, et al. Robotic, totally endoscopic excision of mitral valve papillary fibroelastoma. *Multimed Man Cardiothorac Surg* 2021.
9. Bourdillon A, Elder R, Lalonde M, et al. Robotic mitral valve repair in a patient with cardiac dextroversion. *JTCVS Tech* 2022;11:12-6.
10. Ad N, Luc JGY, Nguyen TC, et al. Cardiac surgery in North America and coronavirus disease 2019 (COVID-19): Regional variability in burden and impact. *J Thorac Cardiovasc Surg* 2021;162:893-903.e4.
11. Chemtob RA, Wierup P, Mick SL, et al. A conservative screening algorithm to determine candidacy for robotic mitral valve surgery. *J Thorac Cardiovasc Surg* 2022;164:1080-7.
12. Amabile A, Hameed I, Shang M, et al. Unilateral percutaneous cannulation and endoaortic balloon management in robotic-assisted cardiac surgery: The least invasive approach. *Multimed Man Cardiothorac Surg* 2022. doi: 10.1510/mmcts.2022.010.

**Cite this article as:** Amabile A, Morrison A, LaLonde M, Agarwal R, Mori M, Hameed I, Bin Mahmood SU, Komlo C, Ragnarsson S, Krane M, Geirsson A. Two hundred robotic mitral valve repair procedures for degenerative mitral regurgitation: the Yale experience. *Ann Cardiothorac Surg* 2022;11(5):525-532. doi: 10.21037/acs-2022-rmvs-73